

Comparative analysis of segmentation techniques of airways on images of chest computed tomography

Tarique da S. Cavalcante, Pedro P. Rebouças Filho,
Paulo C. Cortez, John H. Félix, Marcelo A. Holanda,
Departamento de Engenharia de Teleinformática
Federal University of Ceará
Fortaleza, Brazil

Auzuir R. Alexandria
Insituto Federal de Educação Ciência e Tecnologia do
Ceará
Fortaleza, Brazil

Abstract – The study of pulmonary diseases and its treatments are significantly important, because most of the world population is affected by these diseases, which includes bronchial diseases such as asthma, bronchiectasis and bronchitis. The diagnosis of bronchial diseases is based in the conditions of the airways. Due to this fact, it is very important for the public health care to make and determine correct precocious diagnosis to detect real levels of pulmonary diseases, in which it has a great influence of accurate identification of the conditions of pulmonary airways. For that reason, the airway automatic segmentation is a fundamental step. This study evaluates algorithms based in local analysis of pulmonary densities, active contours and region growing to segment the pulmonary airway. In conclusion, we present satisfactory results for the airway automatic segmentation.

Keywords-airways, segmentation, active contour method, region growing.

I. INTRODUCTION

The study of pulmonary diseases, as well as their treatments is significantly important, due to the fact that among several diseases that affect the world's population, most of them are caused in the lungs, as in bronchial diseases such as asthma, bronchiectasis and bronchitis [1].

Asthma is a diseased that is characterized by the narrowing of airways. The World Health Organization (WHO) estimates that 300 million people in the world have asthma [2].Bronchiectasis causes an unusual and permanent dilatation of the sub segmental airways [3]. Bronchitis, which can be chronic or acute, and is an inflammation of the coating of airways. Chronic Bronchitis is one of the main components for Chronic Obstructive Pulmonary Disease (COPD) [4] [5].

COPD is a disease characterized by the airflow obstruction. Nowadays, "WHO" estimates that 210 million people have COPD in the whole world, and the number of deaths caused by COPD will increase about 30% in the next 10 years [2].

For that reason it's very important for public health care to make and to determine correct early diagnosis to

detect the real levels of bronchial diseases, in which has a great influence of accurate identification of the conditions of pulmonary airways.

Many of the information, presented in medical images, can be obtained by computed vision. This contributes to increase the use of computational vision systems in operations such as; detection, recognition and object classification, parameters estimation, analysis of shapes and scene description [6] [1].

In this system the priority is to obtain images with the information we need, because with this information it's possible to group them by areas. This process is called image segmentation. There are several segmentation techniques applied to airways, but the two best ones are the region growing and the active contours method.

The region growing technique is used in the segmentation of pulmonary airways, presenting significant results, however it has some limitations due to the non-continuous contours of the airways the method of active contours is better than the region growing method, because the latter considers information from the whole contour. To make the segmentation to be automatic we use a method that locates the airways. This method is based on a technique proposed in this article, which is based on the analysis of pulmonary densities.

This study proposes an algorithm and evaluates the pulmonary densities with the region growing and balloon active contours methods to segment the airways automatically.

In section 2 we made a brief review of the previous studies related to lung segmentation and airways in images of the thorax TC. We also discussed the main characteristics of the active contour method. In section 3 we present and describe the steps of the process to detect the stages of bronchial diseases. In section 4 we present some results referring to the steps of location and segmentation of airways. In section 5 we present the conclusion.

II. THEORETICAL FUNDAMENTALS

A TC image of the lungs represents a slice of the thoracic cavity where many structures are found, such

as vessels, arteries, airways, hilum, pleura and pulmonary parenchyma. Each one of them contains specific information.

The diagnosis of bronchial diseases is based in the airway conditions. For that reason, the segmentation of airways is a fundamental step to characterize disease related to the airways.

Mori et al. [7] segment the airways using the region growing method, which is often limited by the non-continuous contours. When there is a sudden change in the segmented area, the process ends.

Buysarat and Zrimec [8] propose the segmentation of airways by templates matching, with low accuracy in little bronchi and arteries, if there is not more than one artery close to the airway (Adjacent ambiguous arteries).

Félix et al. [9] segment the lung's internal structures making no distinction, using mathematic and region growing.

Rizi et al. [10] uses fuzzy connectivity to decrease errors of the region growing, as well as it improves the airways segmentation adding information of shape to decrease the leaking in the region growing [11].

Shi et al. [12] and Cheng et al. [13] use the active contours method to segment the superior airway on TC images of the facial maxillary complex.

A – Active Contour Methods

This method was proposed by Kass [14] and consists of creating a curve around the object we want to study. This curve is conducted, through forces, until the edges of the object and then it evolves in way that its energy decreases in every new interaction. The active contours are the parameterization 2D of a geometrical curve of

$$\begin{cases} [0, 1] \rightarrow \mathbb{R}^2 \\ s \rightarrow c(s) = [x(s), y(s)]. \end{cases} \quad (1)$$

The energy function of the active contour is described by

$$E_S = \int_0^1 \{E_{int}[c(s)] + E_{ext}[c(s)]\} ds, \quad (2)$$

In which $c(s)$ is the curve, E_S is the total energy of the contour, E_{ext} represents the external energy and E_{int} is the internal energy [14].

The external energy E_{ext} represents the part of the energy that consists of external forces, i.e., forces that do not depend on any contour characteristics, but it depends on image proprieties. For that reason, gradient operators are largely used to determine the external energy of active contours.

The internal energy E_{int} represents the fraction of the active contour, formed by internal forces.

These forces depend directly on the contour shape and they are defined by

$$E_{int} = \int_0^1 [e_1 |c'(s)|^2 + e_2 |c''(s)|^2] ds, \quad (3)$$

in which $c'(s)$ represents the first derivative and $c''(s)$ is the second derivative. The terms e_1 and e_2 are evaluation factors to both forces [14].

The parameterization of internal energy of active contour (adjustment of e_1 and e_2) can limit flexibility and to avoid tubular shapes, irregular surfaces and bifurcated shapes. Another limitation of this method occurs when the contour is started inside the object, because inhomogeneous areas the gradient value is null. So, the contour is only influenced by the internal energy, that makes it uniform, and also minimizes its area, and then it collapses [15].

Many studies are carried out proposing new active contour methods (ACM) to avoid these limitations. Lee et al [16] apply the model “level set”, which is one of the geometrical ACM's, in the lung segmentation on TC images. Silva [17] uses the traditional parametrical active contours and the gradient vector flow (GVF).

There are other parametrical ACM's such as the balloon ACM [18], which we will discuss later in this study, due to the information we obtained from books saying that these methods are appropriated for application.

Balloon ACM

Cohen [18] defines a new internal force for ACM, which is called balloon force, to solve the problem of restriction of its beginning inside the object.

The balloon force expands the contour, which is very important for the curve when it is found in homogeneous areas of the image.

The balloon ACM can be implemented based on the centroid of the contour. This coordinate is the central point of the curve, calculated through the average of the coordinates “x” and “y” from all the points in the contour. In this method, the balloon force is based on the Euclides equation of distance. The balloon force is defined for each point of the contour $v_i(x_i, y_i)$ and a given centroid (x_m, y_m) .

In the balloon ACM, the total energy and external energy remain the same as in the traditional method. The internal energy consists of the first derivative of the contour, and also of the balloon force.

B. Region Growing

Region growing is an image segmentation method that consists of gathering pixels or sub areas into big areas, based on some previous rules. The gathering starts with the selection of a set of “seeds” in the areas we want. Then, the pixels next to the seeds are added to the area, incase the considered properties are similar [6].

For the application of the algorithm of region growing, at first we determined the interest area (RI), which can be divided in “n” smaller areas R_1, R_2, \dots, R_n , as shown below by

$$RI = \bigcup_{i=1}^n R_i, \quad (4)$$

in which RI represents the whole area, R_i is a connected area for $i=1, 2, \dots, n$.

C. Local analysis of density

Pulmonary structures have specific density values measured in Hounsfield units (HU). Thus, the main density zones are: hyper airflow areas or hyper distension are from -1000 to -900, normal airflow areas from -900 to -500 HU, little airflow from -500 to -100 HU, With no airflow from -100 to 100 HU and the bone area from 600 to 2000 HU [19].

In figure 1a we can see an image of lung TC multi detectors and also a representation in HU density zones. In figure 1b, each color represents a density zone, in which red shows the areas with hyper airflow. Blue shows the normal airflow areas, green represents the areas with low airflow, yellow shows the areas with no airflow and black represents the bone area.

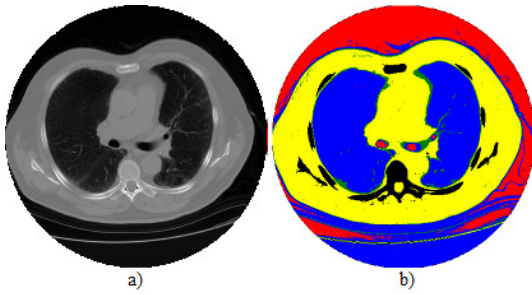


Figure 1. a) Image of TC multi detectors and b) representation in density zones

Based on specific knowledge of pulmonary densities, from TC images, it is possible to identify, through analysis of density rates in each point and also in the adjacent points, which structures belong to the airways. These adjacent points must be proportional to the airways diameter and to the image resolution.

We need to calculate the percentage of each area to determine the airway location. To calculate we assume that there is a group with 5 categories of c_i , in which $i=0,1,2,3$ and 4, organized in the positions: Hyper airflow, normal airflow, a little airflow, with no airflow and bone. We consider $D(x,y)$ a matrix of pulmonary densities and we have the function $f_i(x,y)$ which determines the amount of points with the densities each category of c_i , given by

$$f_i(x,y) = \sum_{l=-3}^3 \sum_{m=-3}^3 R(x-l, y-m), \quad (5)$$

Where R is given by

$$R(x,y) = \begin{cases} 1, & l_i(c_i) < D(x,y) < l_s(c_i) \\ 0, & \text{caso contrario,} \end{cases} \quad (6)$$

In which $l_i(c_i)$ and $l_s(c_i)$ represent the inferior and superior limits of the density zone from the category c_i .

From the $f_i(x,y)$ restates, we calculate the percentage P_i of each category i . Thus, we obtain a binary image $v(x,y)$ given by

$$v(x,y) = \begin{cases} 1, & \text{para } P_3 + P_2 > 0,1 \\ & e P_0 > 0,05, \\ 0, & \text{caso contrario.} \end{cases} \quad (7)$$

The $v(x,y)$ image does not present a full segmentation of airways, as we see in figure 2, but it makes a rotation. In this picture, the image $v(x,y)$ is on the top of the original images, pixels with rates "1" are presented in red and highlights with yellow circles.

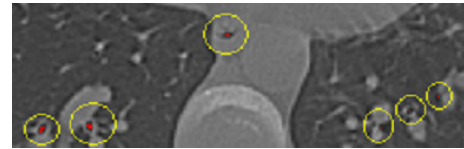


Figure 2. Image $v(x,y)$ on the top of the lung TC image.

III. METHODOLOGY

To perform the automatic and accurate detection of pulmonary airways, we use a set of images from healthy volunteers and from patients with COPD [20]. These images are obtained specifically for a previous research protocol reported in the period from august of 2005 to march of 2006.

We use the algorithm of local analysis of the pulmonary densities. The results of the location are analyzed by a medical specialist.

The airways segmentation is carried out with the region growing method and the balloon ACM. The initial contours for a balloon ACM, as well as the seed for the growth area method are defined by the result of the algorithm of density local analysis.

The method of location and segmentation are evaluated in multi slice TC images of the thorax.

IV. RESULTS AND DISCUSSION

In this section we present the results, obtained for the airway automatic segmentation.

For the location step we evaluated the density local analysis method. The results are presented in figure 3.




Figure 3. Result of the airway automatic location through the density local analysis method.

The 12 tested images contain 71 airways. Of those 71 airways, 62 are correctly located and 8 couldn't be detected, which gives us an accuracy percentage of 87.32%. Even with the false negatives, this method was found to be promising, because it presented solid results on images from several patients.

The balloon ACM and the region growing are tested for a set with 12 images. In picture 4 we present results from some tested images.

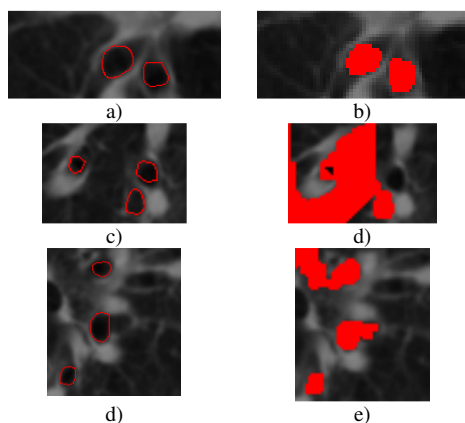


Figure 4. a). c). and d). show the result of segmentation by balloon ACM and b). d). e). show the results by the region growing method.

We noticed a successful segmentation of the balloon ACM. The growth area method, which is largely used in research, obtained lower results than ACMs, in doctors' opinions. In the pictures 4(d) and 4(e), we can notice the error in the segmentation from the growth area method. This error is due to the non-continuous contour or due to the presence of areas, around the airways, similar to the areas inside it.

V. CONCLUSION

This study makes a comparative analysis between the segmentation methods: balloon ACM and region growing, applying them in the airways segmentation in TC images from the lungs. Plus it also tests a method based on the local analysis of density for the location of airways.

We have shown evidence, for the set of images we tested, that the method for the location of airways is promising, presenting solid results in previous visual analysis.

The segmentation of airways using the balloon ACM method presents better performance than the region growing method. The region growing method, applied in airway segmentation, presents some limitations. The most noticeable errors are the ones caused by non-continuous contour, or by similar areas inside and around the airway.

REFERENCES

[1] J. H. S. Felix, "Sistema de visão computacional para detecção e quantificação de enfisema pulmonar," Master's thesis, Universidade Federal do Ceará, 2007.

[2] H. S. Campos and A. C. M. Lemos "A asma e a DPOC na visão do pneumologista," *Jornal Brasileiro de Pneumologia*, n. 35, vol. 4, 2009.

[3] H. A. V. Ortega, "Discinesia ciliar primária: considerações sobre seis casos da síndrome de kartagener," *Jornal Brasileiro de Pneumologia*, n. 33, vol. 5, 2007.

[4] E. Garcia, A. F. S. Junior, F. Schorr, M. Hota, R. G. Brizzi, and A. B. Silva, "Molde brônquico devido ao uso de interferon peguilado e ribavirina," *Jornal Brasileiro de Pneumologia*, n. 35, vol. 7, 2009.

[6] P. Moritz, L. J. M. Steidle, M. B. Felisbino, T. Kleveston, M. M. M. Pizzichini and E. Pizzichini, "Determinação do componente inamatório das doenças das vias aéreas através do escarro induzido: utilização na prática clínica," *Jornal Brasileiro de Pneumologia*, n. 34, vol. 11, 2008.

[7] R. C. Gonzalez and R. Woods, *Digital Image Processing*, 3rd ed., Pearson Prentice Hall, New Jersey, 2008.

[8] K. Mori, J. I. Hasegawa, Y. Suenaga and J. I. Toriwaki, "Automated anatomical labeling of the bronchial branch and its application to the virtual bronchoscopy system," *IEEE Trans. On Medical Imaging*, vol. 2, pp 103-114, 2000.

[9] S. Busayarat and T. Zrimec, "Automatic detection of pulmonary arteries and assessment of bronchial dilatation in hrcr images of the lungs", *IEEE Computational Intelligence Methods and Applications*, pp. 1-5, 2005.

[10] J. H. S. Felix, P. C. Cortez, M. A. Holanda and R. Costa, "Automatic segmentation and measurement of the lungs in healthy persons and in patients with chronic obstructive pulmonary disease in ct images," *CLAIB*, vol.18, pp. 370-373, 2007a.

[11] F. Y. Rizi, A. Ahmadian, E. Fatemizadeh, E. and J. Alirezaie, "An optimization based approach embedded in a fuzzy connectivity algorithm for airway tree segmentation," *30th Annual International IEEE EMBS Conference 4*, 2008a.

[12] F. Y. Rizi, A. Ahmadian, N. Sahba, V. Tavakoli, J. Alirezaie, E. Fatemizadeh and N. Rezaie, "A hybrid fuzzy based algorithm for 3d human airway segmentation," *Bioinformatics and Biomedical Engineering, ICBBE*, pp. 2295-2298, 2008b.

[13] F. Y. Rizi, A. Ahmadian, N. Sahba, V. Tavakoli, J. Alirezaie, J. E. Fatemizadeh and N. Rezaie, "A hybrid fuzzy based algorithm for 3d human airway segmentation," *Bioinformatics and Biomedical Engineering, ICBBE 2008*, pp. 2295-2298

[14] I. Cheng, S. Nilufar, C. Flores-Mir and A. Basu, "Airway segmentation and measurement in ct images," *Proceedings of the 29th Annual International Conference of the IEEE EMBS*, 2007.

[15] M. Kass, A. Witkin and D. Terzopoulos, "Snakes:active contours models," *International Journal of Computer Vision* n. 1, vol. 4, pp 321-331, 1987.

[16] A. Bouhours, "Segmentação do ventrículo em ecocardiogramas usando contornos ativos," Master's thesis, Universidade Federal do Ceará, Fortaleza, 2006.

[17] M. Lee, S. Y. Park, W. Cho and S. Kim, "Medical image segmentation using a geometric active contour model based on level set method," *IEEE Pacific Rim Conference on Communications, Computers and Signal Processing*, pp. 577-580, 2007.

[18] J. S. S. Silva, "Segmentação pulmonar em estudos de tomografia axial computadorizada," Master's thesis, Universidade de Aveiro, 2005.

[19] COHEN, L. D. "On active contour models and balloons," *CVGIV: Image Understanding*, vol. 53, pp. 211-218, 1991.

[20] S. R. R. Vieira, L. Puybasset, J. Richecoeur, Q. Lu, P. Cluzel, P. B. Gusman, P. Coriat and J. J. Rouby, "A lung computed tomographic assessment of positive end-expiratory pressure induced lung overdistension," *American Journal of Respiratory and Critical Care Medicine* vol. 158, pp. 1571-1577, 1998.

[21] G. F. P. Winkler, "Efeitos agudos da administração de pressão positiva contínua em vias aéreas de modo não invasivo sobre o parênquima pulmonar de voluntários sadios nas posições supina e prona," Master's thesis, Universidade Federal do Ceará, Fortaleza, 2006.